



Hepatic safety and efficacy of immunomodulatory drugs used in patients with autoimmune hepatitis

Benedetta Terziroli Beretta-Piccoli^{a,b,c,d,*}, Gustav Buescher^{c,e}, George Dalekos^{c,f}, Kalliopi Zachou^{c,f}, Anja Geerts^{c,g}, Nasser Semmo^h, Mirjam Kolev^h, Eleonora De Martin^{c,i}, Maciej K. Janik^{c,j}, João Madaleno^{c,k}, Milica Lalosevic Stojkovic^{c,l}, Jérôme Dumortier^{c,m}, Thomas Vanwolleghem^{c,n,o}, Ida Schregel^{c,e}, Silja Steinmann^{c,e}, Florence Lacaille^{c,p}, Marcial Sebode^{c,e}

^a Epatocentro Ticino, Lugano, Switzerland

^b Faculty of Biomedical Sciences, Università della Svizzera Italiana, Lugano, Switzerland

^c European Reference Network on Hepatological Diseases (ERN RARE-LIVER), Hamburg, Germany

^d MowatLabs, Faculty of Life Sciences & Medicine, King's College London, King's College Hospital, London, UK

^e I. Department of Medicine, University Medical Centre Hamburg-Eppendorf, Hamburg, Germany

^f Department of Medicine and Research Laboratory of Internal Medicine, National Expertise Centre in Autoimmune Liver Diseases, General University Hospital of Larissa, Larissa, Greece

^g Department of Gastroenterology and Hepatology, University Hospital of Ghent, Belgium

^h Hepatology, University Clinic for Visceral Surgery and Medicine, Inselspital Bern, University of Bern, Bern, Switzerland

ⁱ Hépatologie et Transplantation Hépatique, Hôpital Paul Brousse, Villejuif, France

^j Department of Hepatology, Transplantation and Internal Medicine, Medical University of Warsaw, Warsaw, Poland

^k Liver Disease Unit, Internal Medicine Department, Centro Hospitalar e Universitário de Coimbra, Coimbra, Portugal

^l University Clinical Center of Serbia, Belgrade, Serbia

^m Hôpital Edouard Herriot, Hospices Civils de Lyon and Université Claude Bernard Lyon 1, Lyon, France

ⁿ Department of Gastroenterology and Hepatology Antwerp University Hospital, Antwerp, Belgium

^o Viral Hepatitis Research Group, Laboratory of Experimental Medicine and Pediatrics (LEMP), University of Antwerp, Antwerp, Belgium

^p Hôpital Necker-Enfants Malades, Paris, France

ABSTRACT

Background and aims: There is little data on the hepatic efficacy and safety of immunomodulatory drugs used in patients with autoimmune hepatitis (AIH), despite their established use in dermatology, rheumatology and inflammatory bowel diseases (IBD). Our aim was to collect real-life data on the experience of expert centres in treating AIH patients with these drugs, considered unconventional for AIH management.

Methods: Online survey among hepatology centres being part of the European Reference Network on Hepatological Diseases (ERN RARE-LIVER).

Results: 25 AIH patients have been reported. Ten were female, median age at diagnosis was 28 years; median follow-up was 17 months. All had initially received AIH-standard treatment.

AIH-unconventional treatment was initiated for concomitant autoimmune diseases in 15 cases: nine for IBD (five vedolizumab and four ustekinumab), and one each for following diseases: autoinflammatory syndrome (tocilizumab), chronic urticaria (omalizumab), rheumatoid arthritis (abatacept), psoriasis (guselkumab), psoriatic arthritis (secukinumab, followed by ustekinumab) and alopecia (ruxolitinib). Three patients were treated with immunomodulatory drugs for side effects of previous treatments, including two patients with IBD treated with vedolizumab and ustekinumab, respectively, and one treated with belimumab. At the end of follow-up, 13 patients were in complete biochemical response, the patient on omalizumab had a relapse, and four patients with concomitant IBD had insufficient response. Seven patients were treated for lack of biochemical remission, of whom six with belimumab, all initially reaching complete biochemical response, but five relapsing during follow-up; and one with secukinumab, having concomitant rheumatoid arthritis and ankylosing spondylitis, reaching complete biochemical response. Only the patient on abatacept received unconventional treatment as monotherapy. Side effects were reported in two patients on belimumab: one recurrent soft tissue infections, one fatigue and arthralgia.

Conclusion: Among 25 AIH patients who were treated with immunomodulatory drugs for different reasons, the majority had a favorable course, relapse was frequent in difficult-to-treat patients who received belimumab, and four with concomitant IBD had insufficient response.

* Corresponding author. Epatocentro Ticino, Lugano, Switzerland.

E-mail address: benedetta.terziroli@usi.ch (B. Terziroli Beretta-Piccoli).

<https://doi.org/10.1016/j.jaut.2023.103113>

Received 11 June 2023; Received in revised form 28 July 2023; Accepted 6 September 2023

Available online 15 September 2023

0896-8411/© 2023 The Authors. Published by Elsevier Ltd. This is an open access article under the CC BY license (<http://creativecommons.org/licenses/by/4.0/>).

1. Introduction and aim

Autoimmune hepatitis (AIH) is an uncommon chronic inflammatory liver disease of unknown cause characterized by female preponderance, positive autoantibodies, raised serum immunoglobulin G (IgG) levels and interface hepatitis at liver histology; it progresses to liver cirrhosis if left untreated [1]. First-line therapy, based on corticosteroids and azathioprine, allows to achieve initial disease control in 80–90% of patients [2]. Six-mercaptopurine and mycophenolate mofetil are commonly used as second-line therapy in patients intolerant to first-line treatment [3]. In case of insufficient response to first-line therapy or intolerance to second-line therapy, other immunosuppressive drugs are used as third-line, including tacrolimus, cyclosporin, anti-tumor necrosis factor (TNF) α agents, rituximab, everolimus and cyclophosphamide [3, 4]. Randomized controlled trials are available only for first-line therapy, dating back to the '70s and demonstrating a clear survival benefit of corticosteroids with or without azathioprine as compared to placebo [5–7]. The above listed drugs have been used for decades in the fields of autoimmunity, transplantation and oncology: there is very little reported experience on the hepatic safety and efficacy of newer, immunosuppressive drugs targeting specific steps of the pathogenic pathways in AIH (Table 1). These drugs are widely used in the fields of rheumatology, dermatology and inflammatory bowel diseases (IBD) and can be considered as unconventional therapy for AIH. Since AIH patients frequently have concomitant extrahepatic autoimmune diseases, they are often treated with these AIH-unconventional drugs, whose impact on the course of AIH is poorly known.

The aim of the present study was to collect the real-life experience of liver centres being part of the European Reference Network on Hepatological Diseases (ERN RARE-LIVER) on hepatic safety and efficacy of immunomodulatory, AIH-unconventional drugs.

Table 1
Mechanisms of action of the immunomodulatory drugs reported in the study.

Drug name	Mechanism of action	Approved indications in the USA
Biologic cytokine inhibitors		
Tocilizumab	Anti-IL-6 receptor monoclonal antibody	Rheumatoid arthritis, giant cell arteritis, juvenile idiopathic arthritis, interstitial lung disease associated with systemic sclerosis, COVID-19, cytokine release syndrome
Secukinumab	Anti-IL-17 A monoclonal antibody	Ankylosing spondylitis, axial spondyloarthritis, plaque psoriasis, psoriatic arthritis
Guselkumab	Anti-IL-23 monoclonal antibody	Psoriasis, psoriatic arthritis
Ustekinumab	Anti-IL-12 and IL-23 monoclonal antibody	Psoriasis, psoriatic arthritis
Anti-integrins		
Vedolizumab	Gut-selective anti- $\alpha 4\beta 7$ -integrin monoclonal antibody	Ulcerative colitis, Crohn disease, immune checkpoint-induced colitis
T-cell costimulation blockade		
Abatacept	Fusion protein of CTLA-4 and Fc portion of IgG1 binding to CD80/86 with high affinity	Rheumatoid arthritis, juvenile idiopathic arthritis, psoriatic arthritis
B-cell inhibition		
Belimumab	Anti-B lymphocyte stimulator monoclonal antibody	Systemic lupus erythematosus, lupus nephritis
Janus kinase inhibitors		
Ruxolitinib	Pan-janus kinase inhibitor, leading to inhibition of IL-2, IL-4, IL-6, IL-7, IL-9, IL-15, IL-21, type 1 interferons and interferon- γ	Rheumatoid arthritis, psoriatic arthritis, ankylosing spondylitis, juvenile idiopathic arthritis
Anti-Ig agents		
Omalizumab	Anti-IgE monoclonal antibody	Allergic asthma, rhinosinusitis with nasal polyps, chronic spontaneous urticaria

IL, interleukin; Ig, immunoglobulin.

2. Methods

We carried out an online survey among the ERN RARE-LIVER community to collect their experiences of giving immunomodulatory, AIH-unconventional drugs to AIH patients, both as an AIH treatment or to treat a concomitant extrahepatic autoimmune disease. We define AIH-unconventional immunomodulatory drugs as those that have not been defined as first-, second- or third-line treatment for AIH in the past, i.e. drugs different from 6-mercaptopurine, thioguanine, mycophenolate mofetil, tacrolimus, cyclosporine, anti-TNF α agents, everolimus, cyclophosphamide and rituximab. The electronic case record form included the following clinical variables: gender; age at diagnosis; date of diagnosis; current age decade; anti-nuclear antibody (ANA), anti-smooth muscle antibody (ASMA), anti-actin antibody, anti-neutrophil cytoplasmic antibody (ANCA), anti-liver kidney microsomal (LKM) and anti-soluble liver antigen/liver pancreas (SLA/LP) antibodies status; presence of primary biliary cholangitis (PBC) or primary sclerosing cholangitis (PSC) variant syndromes; AIH treatment history and response to first-, second- and third-line treatments; concomitant extrahepatic autoimmune diseases; reasons for unconventional drug treatment; presence of liver cirrhosis at the time of unconventional treatment start; name, dose and administration route of unconventional drug; start and stop date, and reason for stopping the AIH-unconventional drug; concomitant conventional AIH therapies and their management during AIH-unconventional treatment; alanine-aminotransferase (ALT) and IgG serum levels at unconventional drug start, and after three, six and 12 months of treatment and at last follow-up; side effects of AIH-unconventional treatment; impact of AIH-unconventional drugs on extrahepatic autoimmune disorders; AIH relapses on AIH-unconventional drugs; duration of complete biochemical response to AIH-unconventional treatment; liver transplant status; liver-related death. Complete biochemical response was defined as normal ALT and IgG serum levels; insufficient response was defined as lack of complete biochemical response [8]. Data was collected via a browser-based online survey being available on the EUSurvey platform (supported by the European Commission, ec.europa.eu/eusurvey) in Dutch, English, French, German, Italian, Polish, Portuguese, Spanish, and Swedish language between January 18, 2023 and February 25, 2023. No personal data of the participants was collected. The survey was distributed among ERN RARE-LIVER centres via a newsletter and the news section of the ERN RARE-LIVER website. In accordance with the local ethics committee, no ethical approval was necessary for this anonymous online survey.

3. Results

Fifty-five hepatology centres from 20 European countries answered the survey, of which 18 were pediatric and 37 were adult units. Seventeen pediatric and 25 adult centres had not treated AIH patients with AIH-unconventional drugs. Thirteen centres reported a total of 25 AIH patients who received AIH-unconventional treatment for different indications. Ten patients were female, median age at diagnosis was 28 years (IQR 18–41; range: 2–76), age distribution in years at time of AIH-unconventional treatment start was as follows: six aged 20–29, six aged 30–39, five aged 40–49, three aged 60–69, two aged 50–59, and one each aged 10–19, 70–79 and 80–89. The majority of patients had AIH type 1 (19 were ANA and/or ASMA-positive, one was ANCA and anti-SLA/LP-positive); two patients had AIH type 2, being anti-LKM positive; autoantibody status was not available in three cases. Three had AIH/PBC variant syndrome, and seven had AIH/PSC variant syndrome, of whom six had concomitant IBD. Median follow-up time from AIH-unconventional treatment start was 17 months (IQR 12–26). All patients received steroids as first-line treatment, in combination with azathioprine in 21 of them. Nine had a complete biochemical remission on first-line treatment, of whom eight were switched to second-line treatments for side effects and one was switched to adalimumab for

concomitant psoriatic arthritis. All patients but two received a second-line therapy: 16 mycophenolate mofetil, six 6-mercaptopurine and one 6-thioguanine; complete biochemical remission was achieved in nine of them. While 13 patients did not receive third-line drugs, four received tacrolimus, four anti-TNF α agents, two cyclosporin, one rituximab, and one tacrolimus and everolimus. The vast majority of the patients (22 out of 25) had concomitant extrahepatic autoimmune diseases, the most common being IBD (10 ulcerative colitis and two Crohn's disease; none of the IBD patients had more than one extrahepatic autoimmune condition); concomitant autoimmune diseases of the other patients are shown in Table 2. The reason for choosing an AIH-unconventional drug was treatment of extrahepatic autoimmune conditions in 15 cases, lack of biochemical response in seven cases and side effects of previous treatments in three cases.

The only reported pediatric patient was affected by anti-LKM-positive AIH in the context of autoimmune polyendocrinopathy candidiasis ecto-dermal dystrophy (APECED) syndrome, and was treated with ruxolitinib for alopecia, in combination with steroids and tacrolimus for AIH, being on complete biochemical response at the time of ruxolitinib start and maintaining it after 11 months without side effects; tacrolimus could be discontinued in the further course.

AIH-unconventional treatment was initially given in combination with conventional AIH treatment in all patients; during follow-up, conventional AIH treatment could be reduced in 12 patients and discontinued in two, of whom one is still in complete biochemical response on abatacept monotherapy after 50 months, and one relapsed on omalizumab monotherapy after 33 months. Of note, the patient on abatacept had good control also of her rheumatoid arthritis.

Fourteen patients had elevated ALAT levels at AIH-unconventional treatment start, 11 reaching normalization, including six treated with belimumab for difficult-to-treat AIH (five of these six patients later experiencing a relapse), two treated with vedolizumab for active IBD, one treated with ustekinumab for active IBD, one treated with tocilizumab for autoinflammatory disease and one treated with secukinumab for elevated liver enzymes on anti-TNF α treatment.

The median duration of response on AIH-unconventional drugs was 22 months (range: 9–96, IQR 13–28).

Side effects of AIH-unconventional treatments were reported in two patients, both treated with belimumab: one had recurrent soft tissue infections, and one had fatigue and arthralgia.

All patients were alive at the end of the follow-up and none underwent liver transplantation.

There were two main subgroups of patients in our study population: those with concomitant active IBD who received AIH-unconventional treatment as an IBD therapy, and those treated with belimumab for difficult-to-treat AIH (Fig. 1). All other patients, who are single cases, are shown in Table 2. The first group included nine patients: six were treated with vedolizumab, of whom two received also ustekinumab (one before and one after vedolizumab) and three patients were treated with ustekinumab. While vedolizumab was discontinued in five of six patients for insufficient IBD control, ustekinumab was ongoing in four patients at the time of the study; the only one who discontinued ustekinumab underwent total colectomy for active IBD despite having received vedolizumab after ustekinumab. Of these nine patients, five had elevated ALAT levels at treatment start, of whom three achieved both ALAT normalization and good IBD control on vedolizumab (2 patients) or ustekinumab (1 patient), and two did not achieve neither ALAT level normalization nor IBD control on vedolizumab.

The second group included six patients who were treated with belimumab for difficult-to-treat AIH. All had insufficient response to first-line therapy with steroids and azathioprine, and to second-line therapy with MMF; two were subsequently treated with cyclosporine, again not reaching remission. Two of them were still on belimumab at the time of the study, one maintaining complete biochemical response after 25 months on combined therapy with prednisone and cyclosporine, and one having experienced a relapse after 22 months on combined therapy with cyclosporine, managed with steroids; the remainder four patients had AIH relapse after a median remission time of 18 months, all being successfully treated with rituximab.

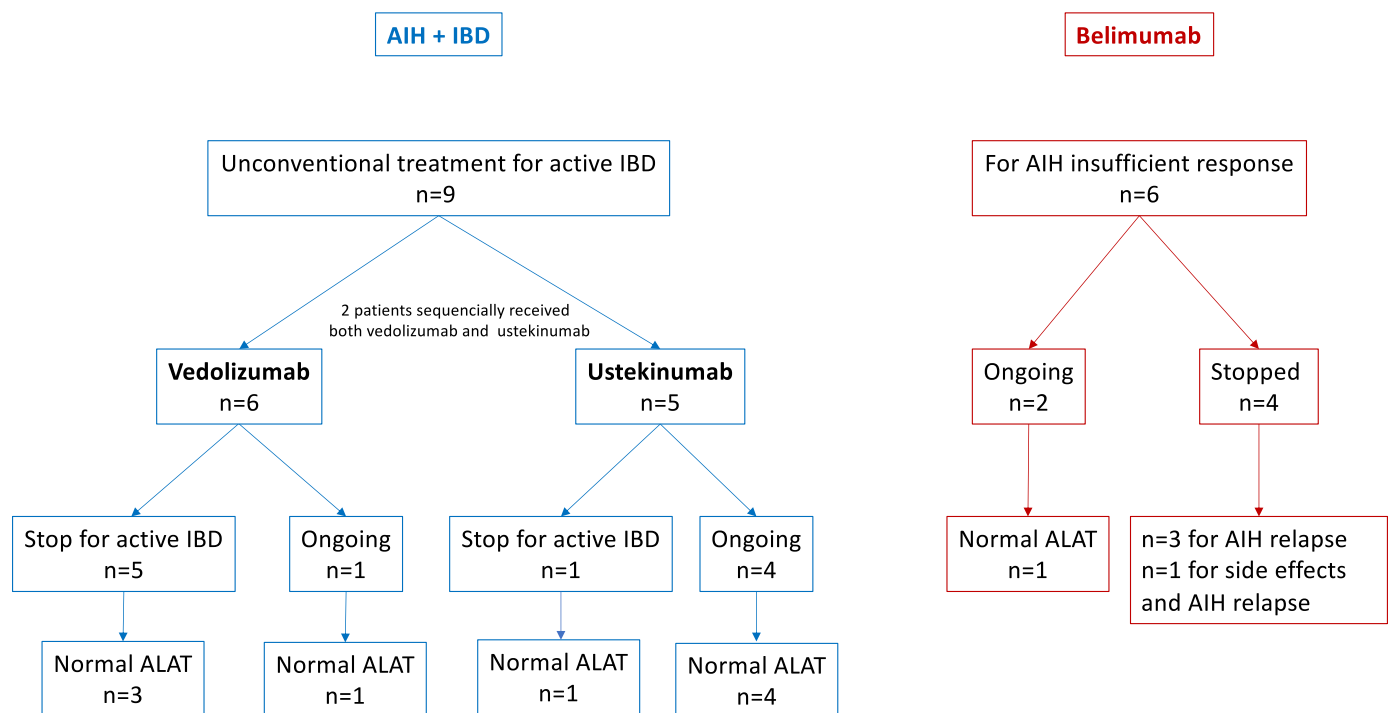


Fig. 1. Graphical representation of the clinical features of the two main autoimmune hepatitis patient groups: 1. Patients with concomitant inflammatory bowel disease who received vedolizumab and/or ustekinumab for active inflammatory bowel disease. 2. Patients with insufficient response to AIH-conventional treatment who received belimumab as an AIH treatment. AIH, autoimmune hepatitis; IBD, inflammatory bowel disease.

Table 2

Clinical features of autoimmune hepatitis patients not included in Fig. 1.

Patient ID	Gender	Age at diagnosis, years	Concomitant extrahepatic autoimmune diseases	Immunomodulatory drug name	Reason for immunomodulatory drug	ALAT normal before unconventional treatment start	ALAT normal at end of follow-up	IgG normalization	Side effects
1	M	27	Auto-inflammatory syndrome – interferonopathy-like	Tocilizumab	Treatment of the systemic disease	No	Yes	Unknown	None
2	M	32	Rheumatoid arthritis and ankylosing spondylitis	Secukinumab	High liver enzymes on anti-TNFα for ankylosing spondylitis	No	Yes	Yes	None
3	F	67	Systemic lupus erythematosus and chronic urticaria with angioedema	Omalizumab	Chronic urticaria	Yes	No	No	None
4	F	30	Crohn's disease	Vedolizumab	Side effects of previous treatments	Yes	Yes	Yes	None
5	F	41	Sjögren syndrome	Belimumab	Side effects of previous treatments	Yes	Yes	No	Fatigue and arthralgia
6	M	25	Psoriasis	Guselkumab	Psoriasis	Yes	Yes	Yes	None
7	M	25	Ulcerative colitis	Ustekinumab	Side effects of previous treatments	No	No	No	None
8	F	47	Rheumatoid arthritis	Abatacept	Rheumatoid arthritis	Yes	Yes	Yes	None
9	M	2	APECED	Ruxolitinib	Alopecia	Yes	Yes	Yes	None
10	F	8	Psoriatic arthritis	Sekukinumab first, ustekinumab later	Psoriatic arthritis	Yes	Yes	Yes	None

ALAT, alanine-aminotransferase; IgG, immunoglobulin G; APECED, autoimmune polyendocrinopathy candidiasis ecto-dermal dystrophy.

4. Discussion

We collected a cohort of 25 AIH patients who were treated with AIH-unconventional drugs for three indications: 15 for concomitant extrahepatic autoimmune diseases, seven for difficult-to-treat AIH and three for side effects of previous treatments. Six of the 14 patients with elevated ALAT levels before AIH-unconventional treatment, reached long-term complete biochemical response. Among the seven patients with difficult-to-treat AIH, two reached complete biochemical response, one on belimumab and one on secukinumab, and five had AIH relapse after a median remission time of 22 months.

Only one patient could be treated with an AIH-unconventional drug as monotherapy, i.e. one female patient with rheumatoid arthritis who remained in complete biochemical response on abatacept monotherapy for 50 months; rheumatoid arthritis was also well controlled on abatacept only. Abatacept is a recombinant fusion protein acting by down-modulating the CD28-mediated costimulatory signal required for T cells activation. Since AIH is considered a T cell-mediated disease, abatacept might represent an attractive AIH treatment option and should be further investigated. A phase 1 clinical trial investigating abatacept as a treatment of post-liver transplantation AIH has been terminated for insufficient recruitment (NCT04203875).

In conclusion, we report 25 AIH patients who were treated with a variety of AIH-unconventional drugs, mostly in an attempt to treat concomitant extrahepatic autoimmune diseases: ALAT normalization could be reached in a subgroup of those who had elevated ALAT levels at treatment start; control of the concomitant extrahepatic autoimmune disease was often associated with good AIH control, and relapse was frequent in difficult-to-treat patients who received belimumab.

Since randomized controlled trials are difficult to perform in this rare and heterogenous population, registries data may be very informative on safety and efficacy of AIH-unconventional treatments in AIH patients.

Data availability

I have shared my data as supporting file.

References

- [1] B. Terziroli Beretta-Piccoli, G. Mieli-Vergani, D. Vergani, Autoimmune hepatitis, *Cell Mol Immunol* (2021), <https://doi.org/10.1038/s41423-021-00768-8>.
- [2] European association for the study of the liver, EASL clinical practice guidelines: autoimmune hepatitis, *J. Hepatol.* 63 (2015) 971–1004, <https://doi.org/10.1016/j.jhep.2015.06.030>.
- [3] A.W. Lohse, M. Sebode, M.H. Jørgensen, H. Ytting, T.H. Karlsen, D. Kelly, M. P. Manns, M. Vesterhus, European reference Network on hepatological diseases (ERN RARE-LIVER), international autoimmune hepatitis group (iaihg), second-line and third-line therapy for autoimmune hepatitis: a position statement from the European reference Network on hepatological diseases and the international autoimmune hepatitis group, *J. Hepatol.* 73 (2020) 1496–1506, <https://doi.org/10.1016/j.jhep.2020.07.023>.
- [4] B.T. Beretta-Piccoli, G. Mieli-Vergani, D. Vergani, Autoimmune hepatitis: standard treatment and systematic review of alternative treatments, *World J. Gastroenterol.* 23 (2017) 6030–6048, <https://doi.org/10.3748/wjg.v23.i33.6030>.
- [5] G.C. Cook, R. Mulligan, S. Sherlock, Controlled prospective trial of corticosteroid therapy in active chronic hepatitis, *Q. J. Med.* 40 (1971) 159–185.
- [6] W.H. Summerskill, M.G. Korman, H.V. Ammon, A.H. Baggenstoss, Prednisone for chronic active liver disease: dose titration, standard dose, and combination with azathioprine compared, *Gut* 16 (1975) 876–883.
- [7] R.D. Soloway, W.H. Summerskill, A.H. Baggenstoss, M.G. Geall, G.L. Gitnick, I. R. Elveback, L.J. Schoenfield, Clinical, biochemical, and histological remission of severe chronic active liver disease: a controlled study of treatments and early prognosis, *Gastroenterology* 63 (1972) 820–833.
- [8] S. Pape, R.J.A.L.M. Snijders, T.J.G. Gevers, O. Chazouilleres, G.N. Dalekos, G. M. Hirschfield, M. Lenzi, M. Trauner, M.P. Manns, J.M. Vierling, A.J. Montano-Loza, A.W. Lohse, C. Schramm, J.P.H. Drenth, M.A. Heneghan, International autoimmune hepatitis group (IAIHG) collaborators(†), systematic review of response criteria and endpoints in autoimmune hepatitis by the international autoimmune hepatitis group, *J. Hepatol.* (22) (2022) S0168–S8278, <https://doi.org/10.1016/j.jhep.2021.12.041>, 00012–5.